



Confidence in your smile

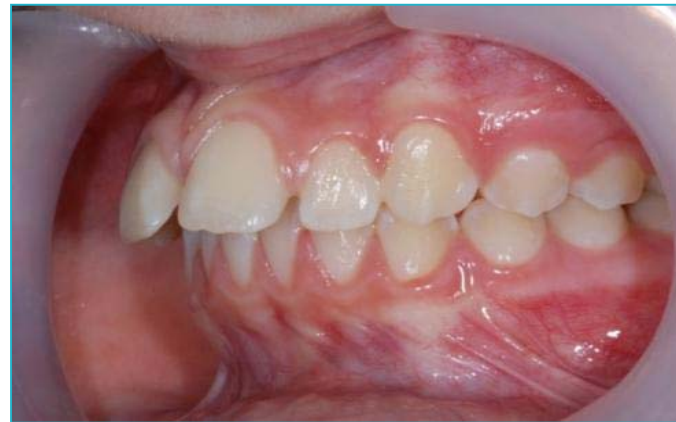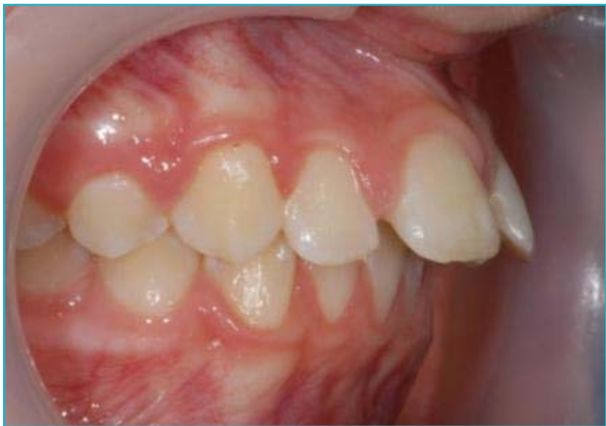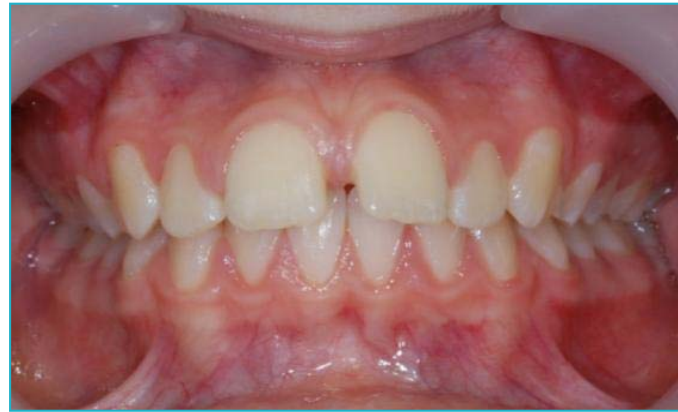presents

DAMON[®]**3**
MX

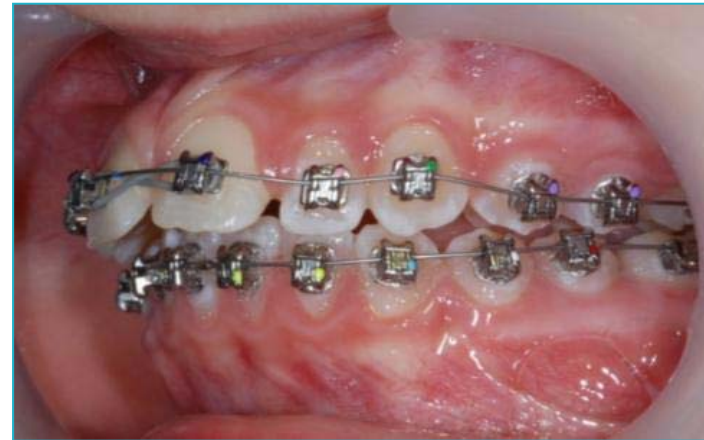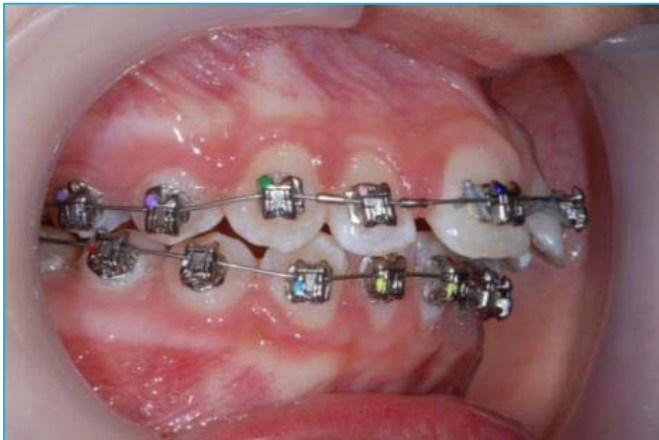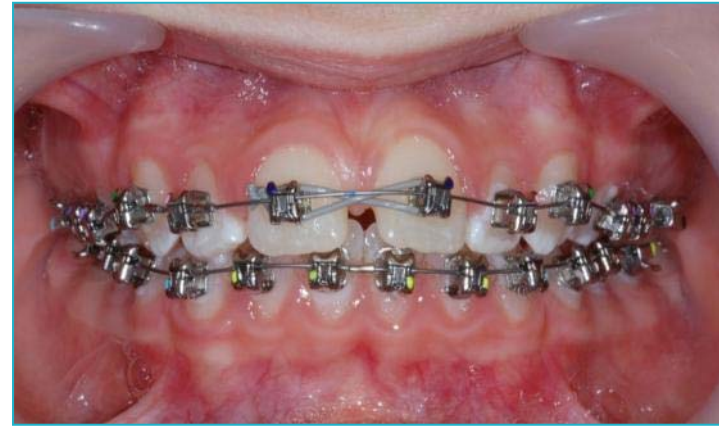


At 11 years of age, Sarah was very concerned about the appearance of her front teeth which were prominent and spaced.

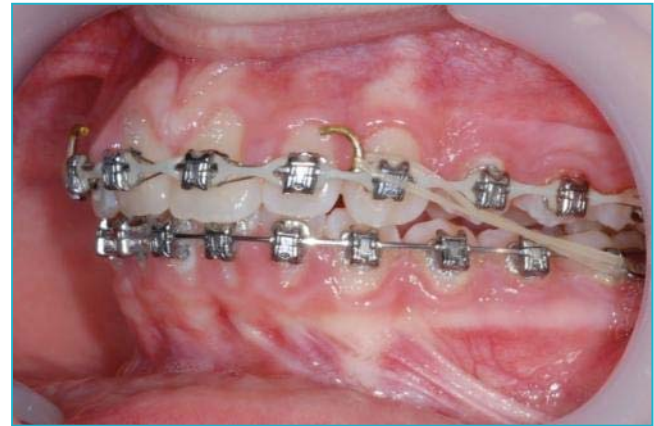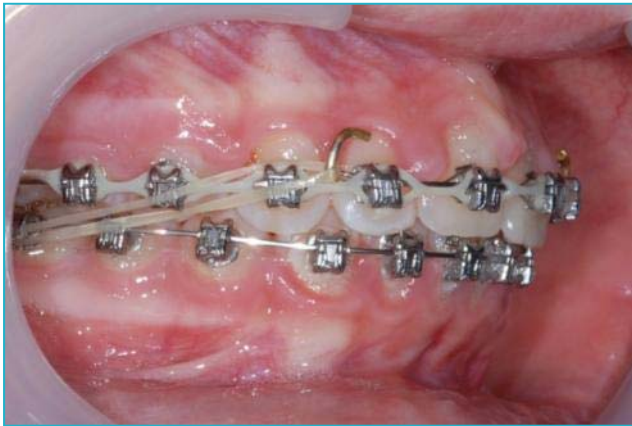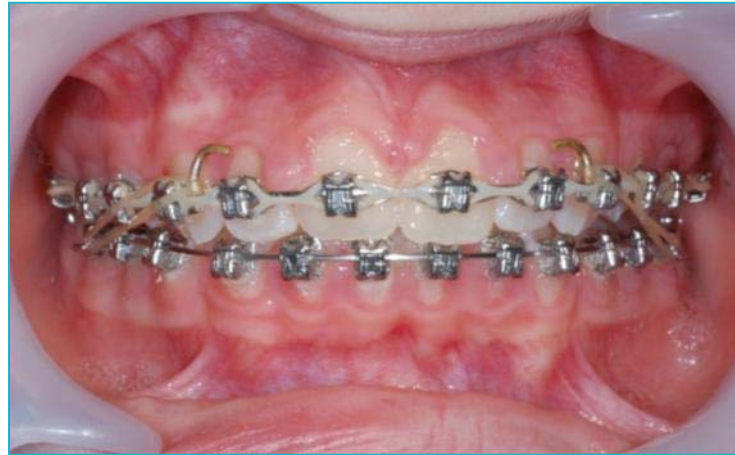The upper incisors were forward by 9mm and there was a marked upper midline space (diastema).



Dr David Horobin used a Damon 3MX
Brace

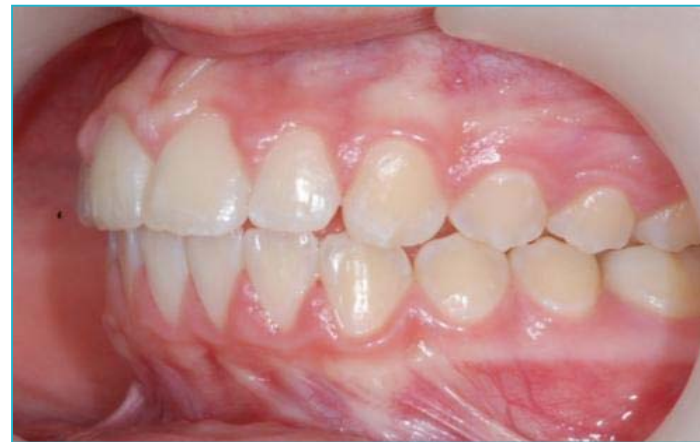
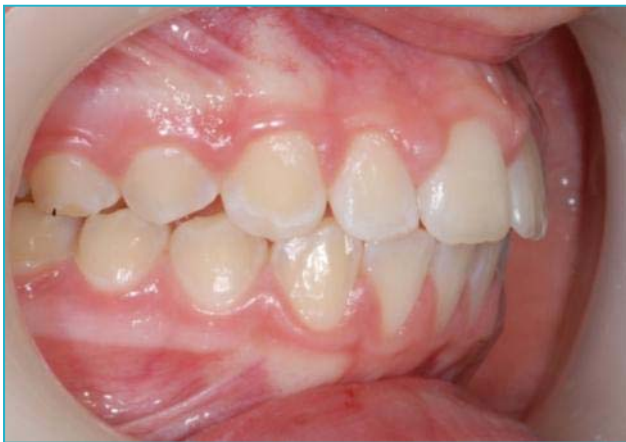
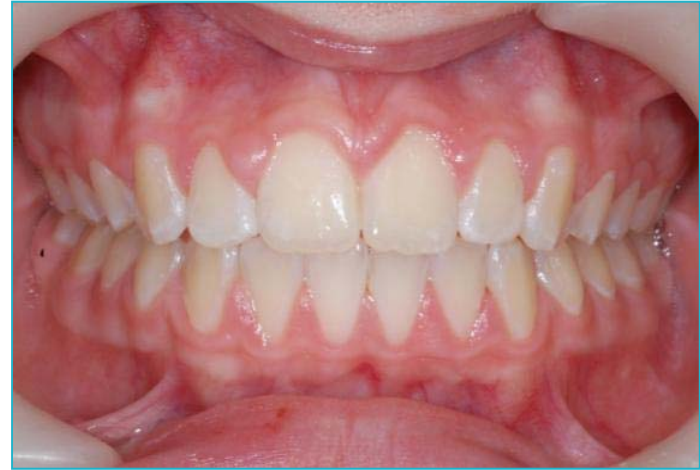Progress after 4 months

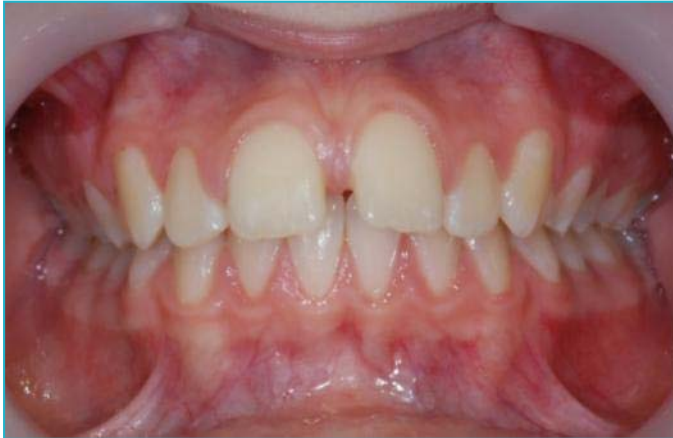



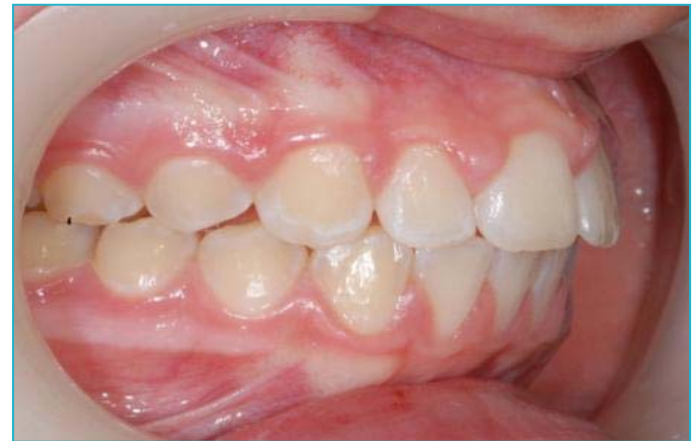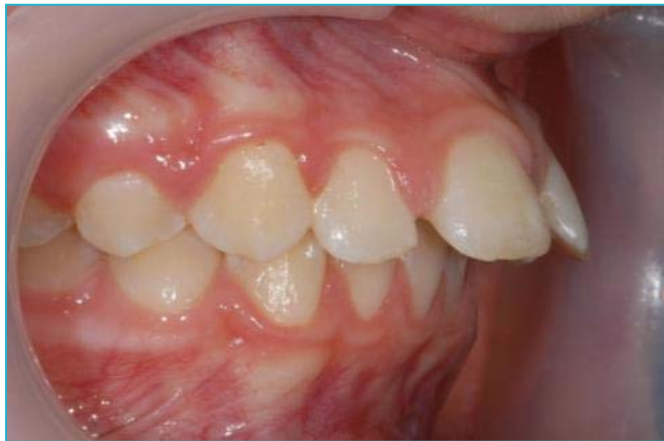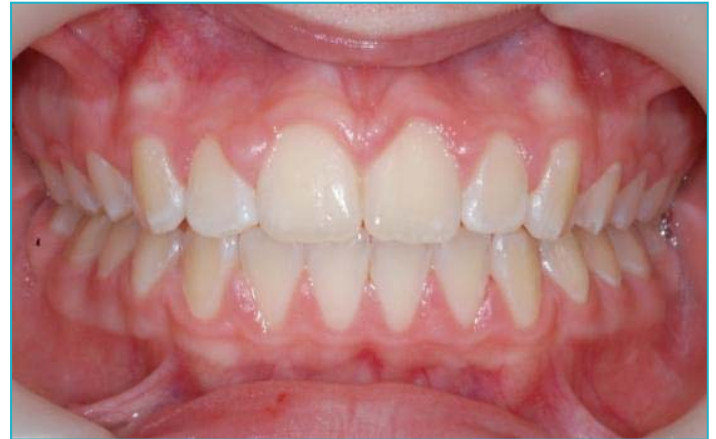Finished Result



Before



After



8 months treatment, without extractions

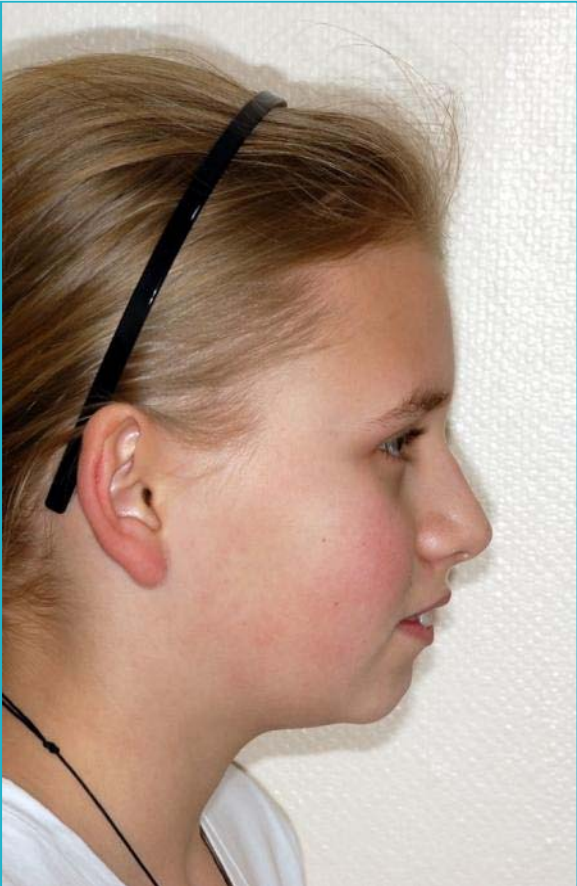Before



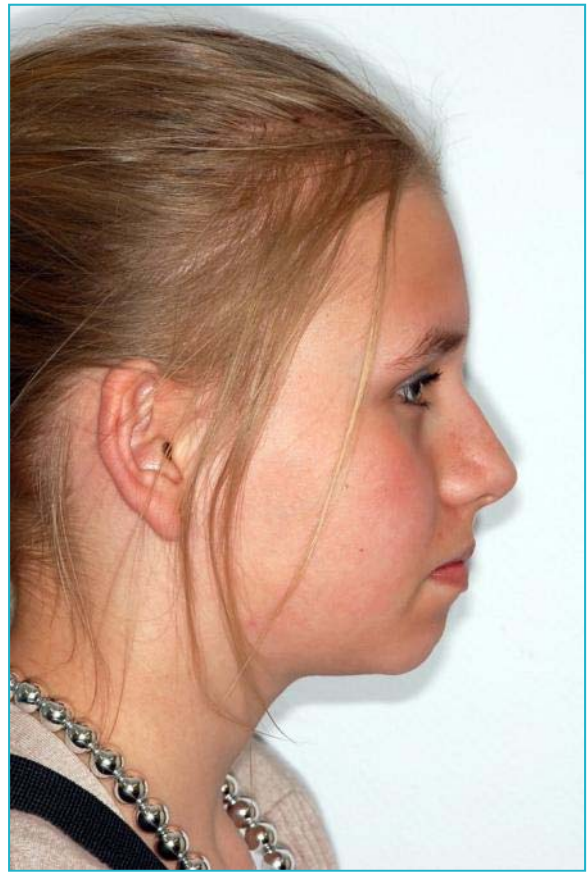After



Before



After



Smile Created by



Confidence in your smile